

CRDs: CAST OR PREFABRICATED?

PART I

Assoc. Prof. Dr. Valeria Covrig, Lect. Dr. Ardelean Gavrilă Liviu, Assist. Lupulescu Teodora Eva, PhD
candidate

“VASILE GOLDIȘ” WESTERN UNIVERSITY OF ARAD FACULTY OF MEDICINE, PHARMACY AND DENTISTRY
DENTISTRY AND DENTAL TECHNOLOGY

ABSTRACT. Dentistry is often confronted with damaged teeth which patients wish to keep in their oral cavity for restoration. Of the same opinion are practitioners who know that a recovered root is better than nothing or an implant. The prosthetic recovery method is called coronal substitution and is currently carried out in two strokes, with the aid of a coronal-radicular device and a total coverage crown, which requires collaboration with the dental laboratory. Failures, clinical rebound, as well as progress made in this field, have led to the appearance of prefabricated CRDs, thus reducing demand for cast metallic CRDs. This research seeks to establish whether cast CRDs are more useful and what types of prefabricated CRDs are convenient for use. The article will present theoretical data resulting from lengthy clinical experience and cases solved with four types of CRDs: cast metallic, prefabricated metallic Dentatus, prefabricated from carbon fibers and glass fibers. The actual tests shall be discussed in other articles.

KEYWORDS: damaged tooth, cast CRD, prefabricated CRD.

INTRODUCTION

Dentists very often face situations in which patients require the morpho-functional restoration of the oral cavity with severely damaged teeth.

They were destroyed following the evolution of coronal lesions or were conservatively and/or prosthetically restored over time.

They do not provide sufficient resistance and retention for coronal restoration, and the question is raised whether they must be extracted.

Based on this controversy, the attitude must not be preconceived (i.e. that they must be extracted), but methods for keeping them should be sought. Of course, we must consider indications and contraindications, as well as the fact that a natural tooth is most of the times better than an implant. This statement is supported by the following arguments:

- the dento-alveolar connection is preserved through a supportive periodontium, which can never be the same in the case of an implant
- neuro-receptors are preserved in the periodontium, meaning that patients feel better with their own root than with an implant or even worse, removable dentures
- periodontal bone resorption does not occur.

If a decision is made to keep that tooth, it means that its implantation is good in terms of position and depth, or a correct endodontic treatment, solving periapical processes (through conservative or surgical

treatment), can be undertaken.

The purpose of this paper is not to detail or research aspects concerning pre-prosthetic stages. Its interest is in the possibilities for prosthetic restoration of these teeth, so as to offer resistance, long-term durability, functionality, esthetics. It must also be a guide for dentists and dental technicians and justify the proportion of one method or another.

Current practice shows that the number of cast CRDs has decreased in favor of using prefabricated CRDs.

History. Throughout time, several coronal substitution methods were found, experimented with and utilized, involving a large number of materials and procedures.

The first method to be described and used (**Fouchard**) was coronal substitution. It was then perfected by other authors, and **Richmond** launched it into mainstream use. Under the form described by him (coronal device in the form of a tooth, coronal cap and anchoring radicular device), it has been used until today, while changing the alloys from which it made in the laboratory (from gold alloys to those containing silver, copper, cobalt-chrome etc.) and sometimes the shape of the coronal abutment preparation and, implicitly, of the cap.

In times when only this method existed, positive results were appreciated, but some difficulties in application or failures in use have also been noted.

This demonstrates that no restoration method

is perfect, but that it is perfectible.

As a consequence, substitution transitioned to a new stage, namely CRDs (CDs and RDs) made from one piece, with a separate total coverage crown. This method bears the name of two-stroke substitution. It allows the wide-scale use of non-noble alloys and the reuse of the tooth-device ensemble when the superjacent crown is lost.

The alloys most commonly used in recent times are Co-Cr. and Cr-Ni (cheap).

For this method, too, we have a sufficient clinical rebound to discuss and draw some conclusions.

It has been noted that, by using both methods, it is possible for the root to break, sometimes after not too long a period of time since the aggregation and in the absence of any overwhelming functional strain.

This is why causes were looked for on several directions.

The first to be studied was the field, which is represented by a pulpless radicular residue. This has the following characteristics:

- The trophicity of hard tissues is no longer ensured. They lose their function in regulating osmotic flow and the direction of circulation through the semi-permeable biological membrane, represented by the enamel, which turns from centrifugal to centripetal. Under these conditions, tooth resistance to aggression greatly decreases.
- Protoplasmic residues from Tomes fibers and the organic substance of enamel change their physical elasticity constants, and therefore their prism support function, and the tooth can no longer cope with all the mechanical strains.
- The loss of some pulp and humoral tissue elements with a role in phagocytosis and antibody formation, which prevents the onset of chemical and biological mechanisms that oppose bacterial diffusion.
- The disappearance of primary odontoblastic and mesenchymal cells, which further entails the disappearance of dentin neoformation processes.
- The destruction of the pulp's reception and transmission apparatus makes it impossible for the cortex and the subcortical centers to act correspondingly during strains exerted on the tooth.

The conclusion is the field becomes fragile, more or less depending on the time elapsed since depulping or pulp mortification.

To obtain a cast CRD, preparation is conducted according to generally valid rules, adapted to the individual's clinical situation of both the remaining coronal portion of the tooth and the root.

This preparation has the role of allowing an easy aggregation of the CRD, but at the same time it targets a root that has been made fragile by the carious process, endodontic access and treatment, devolutionary physiological processes, repeated functional and para-functional stresses, conservative and prosthetic treatments etc.

Adding to this is the dentist's operating mode (more aggressive, extensive or preventive, parsimonious etc.)

In time, practitioners have noticed that failure appears not only due to fragile support, but also to an unexpected, even erroneous (lack of knowledge, iatrogeny) mode of preparation.

Another idea was that of RD corrosion, which leads to its or the root's fracture, and even to the migration of resulting ions, peridentally or even remotely. This resulted in the removal from the market of alloys most susceptible to corrosion.

Yet another was that of the shape of preparation of the tooth's coronal and radicular portion.

And the conclusion reached here was: the cylindrical-conical coronal shape, the cylindrical-conical shape with a rounded tip of the RD, the diameter of the RD - 1/3 of the root's diameter, its length of 2/3 of root length, are as many elements ensuring success for such restorations.

Likewise, the use of any antirotational CRD method is welcomed, as is the existence a dental coronal portion of a 1-2 mm height, which will then be covered with the actual crown.

Other ideas that have aroused discussions and experiments have been: the elasticity module of the CRD and the fixing material, as well as the resistance to stress of the tooth-device ensemble (size, duration, direction).

All these studies have revealed the method's imperfections, which led to a clearer definition of each step in dental restoration by cast DCR using the two-stroke technique.

At the same time, it generated the search for methods that must also meet other needs, like using cheaper, less demanding and less time-consuming materials, while also being resistant and biocompatible.

This resulted in the emergence of prefabricated metallic CRDs.

In the beginning, the radicular shape was cylindrical or conical, with a varying shape of the tip (flat, conical) and accessories on the lateral sides of the RD.

They were made mostly of stainless steel.

In time, the method became so popular among practitioners that it started to be used less rationally, which led to numerous failures. These may be due to the shape and composition of CRD, and to erroneous preparation, fixation or indication.

Studies and failures have in turn generated the emergence of a plethora of other, greatly improved types of prefabricated CRDs (shapes and materials), which may create difficulties for practitioners, who do not know what to choose and do not enough time for research.

This is why specialized literature continues to describe all of these types, classify them according to some criteria and underline their advantages and disadvantages.

Although high-performance prefabricated metallic CRDs have been achieved, experts reached the conclusion that they, too, were not perfect from certain points of view, and new solutions were sought again.

Problems reported now are: when metallic CRDs break, most of the times they cannot be removed from the canal and the tooth can no longer be recovered, and there is also an increased elasticity module with respect to dentin.

This led to fiber-based RD (carbon, polyethylene), which have an elasticity module close to that of dentin and which can be destroyed using milling cutters, drills and solvents, without affecting dental tissue, but have an inappropriate color.

Attempts to adapt to the rigors of aesthetics have led to the appearance of CDs made from quartz fibers or coated with quartz fibers (colored in white), then ceramic (more expensive and more difficult to obtain) and glass fiber CRDs.

The latter are very popular at the moment and do not have sufficient clinical rebound.

In this paper we study one from each of the above-mentioned CRD categories.

We will begin by presenting clinical cases where such devices were used, then move to the experimental part.

Clinical case no. 1

Patient P.I., 26, came to the dental office with massive coronal destruction on incisor 22 and some satisfactory previous odontal and prosthetic restorations. After checking the quality of endodontic obturation, the dentist indicated a cast CRD and a fixed, mixed prosthesis, for which all the conditions existed (fig. 1).

The coronal abutment was prepared according to classic rules, softened dentin was excised, the radicular slot prepared with Peeso milling cutters and a cervical slot with an anti-rotational role. The CRD was cast after a mockup of self-polymerizable acrylate (Duracryl, Spofa) (fig. 2). The device was sandblasted. Cementing was done with zinc phosphate cement (Hardvard). The final fixed prosthesis was made from a Cr-Co alloy, coated with composite diacrylic resin (fig. 3).

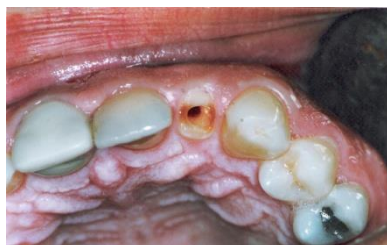

Fig. 1. 22 Preparation for cast CRD

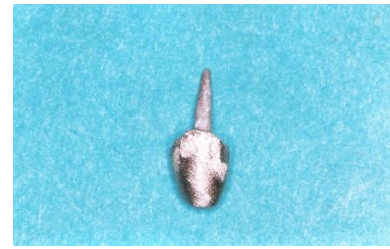

Fig. 2. CRD made from Co-Cr

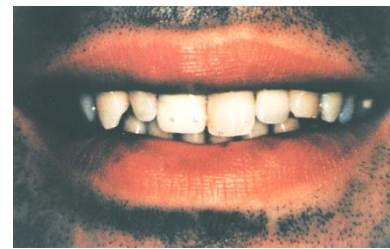


Fig. 3. Situation with metalo-composite total coverage crown

Clinical case no. 2

The patient, M.E., 40, had massive coronal destructions on 12, 21, 22 and 23, which had been restored with multiple cast CRDS (fig. 4) and a fixed metalo-acrylic arcade prosthesis (fig. 5)

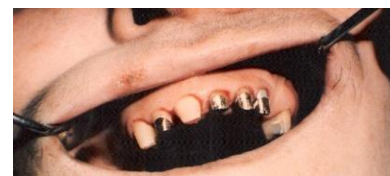

Fig. 4. Metallic CRDs on the maxillary frontals

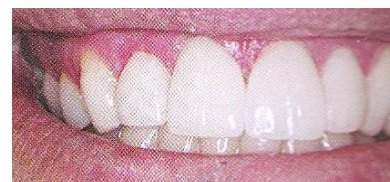

Fig 5. Final appearance of prosthesis

Clinical case no. 3

The patient, P.S., 35, came to the dental office for odontal and prosthetic treatment. The clinical examination found multiple odontal lesions, incipient marginal periodontitis, edentated bi-maxillary gaps of small stretch, with inappropriate prosthesis (fig. 6). 47 and 37 are treated endodontically. Artificial Dentatus pivots (fig. 7 and 8) were applied, with metalo-acrylic FPP prosthesis (fig. 9).

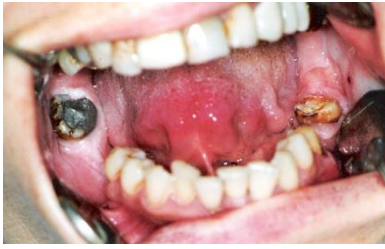

Fig.6. 47 and 37 with massive coronal destructions

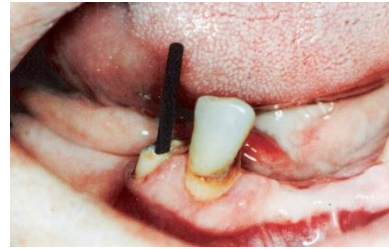

Fig. 10. 44 with carbon-fiber CRD.

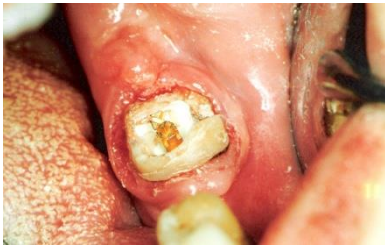

Fig. 7. 37 after endodontic treatment and application of a prefabricated metallic Dentatus CRD.

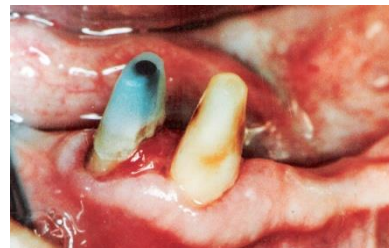

Fig. 11. 44 Abutment restoration with composite

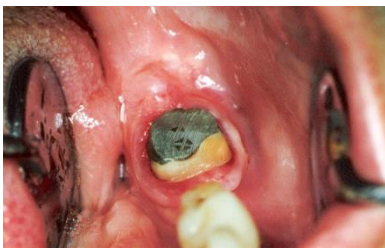

Fig. 8. 37 after abutment restoration with silver amalgam.

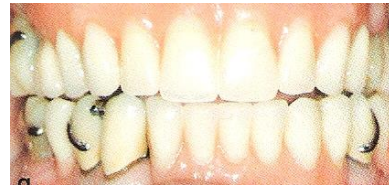

Fig. 12. Final appearance of prosthesis

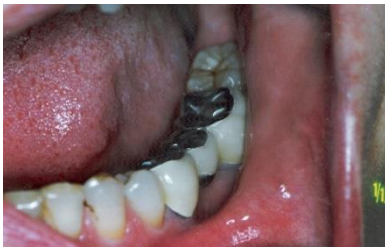

Fig. 9. Final appearance of prosthesis

Clinical case no. 5

The patient, C.I., 20, had an accidentally fractured 11.

Clinical examination found: tartar, dental plaque, inappropriate obturations, secondary caries, especially in the maxillary frontal group.

On the paraclinical examination: X-ray examination on 11 showed correct canal obturation with no periapical reactions. (fig. 13)

Pre-prosthetic treatment consisted of: scaling, brushing, abutment restoration on 11 with ER Dentin Post (from composite reinforced with a glass fiber pivot), after which it was covered with an integrally ceramic crown from IPS.E.max., done by pressing. (Fig. 14)

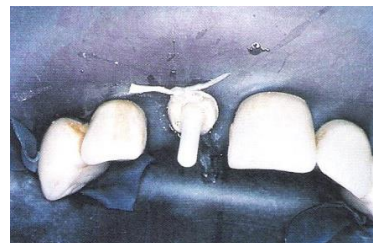
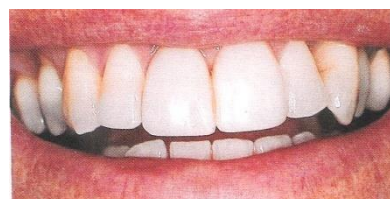

Fig. 13. 11 with glass fiber CRD.



Clinical case no. 4

The patient, T.M., 53, came to the dental office with mandibular re-prosthesis. Clinical examination found a fractured fixed prosthesis made of gold alloy, with abutments on 34, 37 and partial de-cementing of the fixed prosthesis with 44 and 46 as abutments. The restoration of abutments on 34 and 44 was achieved with devices made from carbon fibers and composite materials, after which they were covered with fixed prostheses and a removable FPP T-F-T (Fig. 10, 11, 12).

Fig. 14. Final prosthetic restoration.

CONCLUSION

Coronal substitution is a very common method of prosthetic treatment among practitioners.

It is known today under the name of two-stroke prosthetic restoration of devital teeth. It targets teeth with extensive coronal or coronal-radicular destruction.

The cast (metallic or ceramic) CRD technique requires collaboration with a dental technology laboratory.

The prefabricated CRD technique is cheaper and faster and does not require collaboration with a dental technician.

In both cases, failures have been observed. Also noted was the decrease in the number of requests for cast CRDs.

Clinical cases used in this study were treated according to indications, contraindications and particularities, with CRDs from 4 large known groups.

Immediate results were very good for all cases.

In time, however, failures (fractures, de-cementing) were reported as well.

The 2nd part of the paper will present studies on detecting the causes for weaknesses in these CRDs.

REFERENCES

1. Bratu, R. Nussbaum- Bazele clinice și tehnice ale protezării fixe, Editura Signata, Timișoara, 2000.
2. Bratu Dorin. Materiale dentare în cabinetul de stomatologie. Editura Helicon, Timișoara, 1998.
3. Covrig Valeria. Restaurarea dinților cu tratament endodontic, Ed. Signata, Timișoara, 2000.
4. Covrig Valeria . Proteza fixă unidentară- Curs pentru anul III ,, Vasile Goldiș,, Unuverity press 2001
5. Irfan Ahmad UK. Reatașarea și reconstrucția incisivilor centrali maxilari fracturați. Cosmetic dentistry an IV, nr. 3: 14-21, septembrie 2011.
6. Irfan Ahmad. Compobond: Evoluția unui nou material dentar restaurativ. Cosmetic dentistry an IV, nr. 4: 21-32, octombrie 2011.
7. Nussbaum R. Afecțiunile coronare ale dinților și tratamentul lor protetic. Microproteze , Lito IMT 1986.
8. Pereira Leandro. Microchirurgia periapicală utilizată pentru îndepărtarea unui instrument endodontic fracturat. Cosmetic dentistry an IV, nr. 2: 14-17, aprilie 2011.
9. Rândașu I. Proteze dentare. Editura Medicală, București 1987.
10. Weber Julian, UK, Pierre Machtou, Wihelm Pertot, Franța, Sergio Kutter, Clifford Ruddle, John West SUA: Sistemul WaveOne format dintr-un ac de reciprocitate. Cosmetic dentistry an IV, nr. 3: 08-13, septembrie 2011.